



OncoDiagnostic Laboratory, Inc.

Diagnostic Cytology, Histology, and Molecular Pathology

Cirilo F. Galang, M.D., Lab Director
Chanho H. Park, M.D., Co-Director
Young S. Park, M.D., Pathologist
Han Xu, M.D., Ph.D., Pathologist
Mahmood Aijazi, M.D., Pathologist

812 Huron Road, Suite 520, Cleveland, OH 44115 ♦ Toll Free: (877) ONCO-LAB ♦ Fax: (216) 861-1720 ♦ Website: www.oncodiagnostic.com

Account Name & Address

ODL
DR. CHANHO H. PARK
812 HURON ROAD, SUITE 520
CLEVELAND OH 44115

Fax:
Phone: 216-861-5846

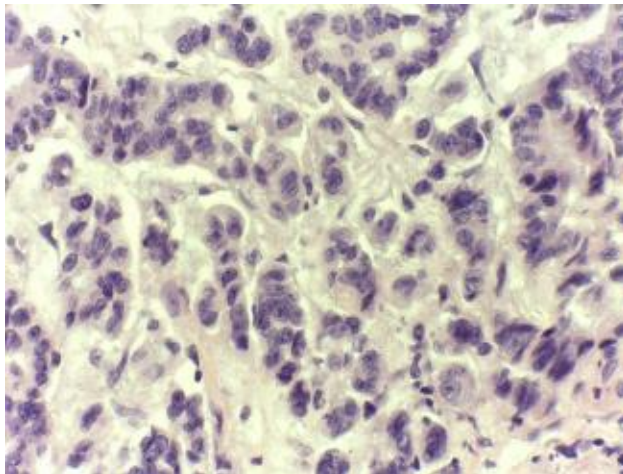
Referring Physician: DR. JOHN MIRRO

Patient Name: DOE, JOHN
Case Number: S2001-009697.1
Soc. Sec. No: 1396007
Date of Birth: 04 14 1920
Age: 81
Sex: M
Collection Date: 11 30 2001
Date Received: 12 04 2001

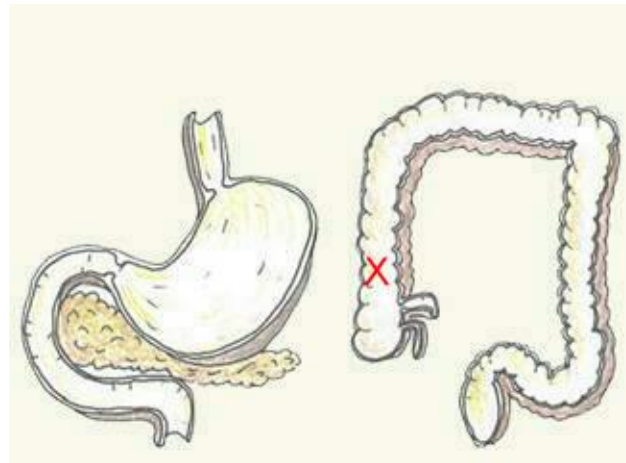
Clinical Information

Past clinical history: weight loss
Clinical symptoms and signs: weight loss
Pre-op Dx: abdominal ct.
Post-op Dx: ca colon
Endoscopic findings: mass

Image



Ascending Colon Biopsy (Mag. x400)



Biopsy Site

Diagnosis

COLONOSCOPY & ASCENDING COLON MASS BIOPSY:
- INVASIVE MODERATELY DIFFERENTIATED ADENOCARCINOMA.

CIRILO F. GALANG, M.D.
(Signed Out 12 20 2001)

Gross Description

Received in Oncofix II are 3 fragments of white-tan soft tissue measuring 0.3 x 0.3 x 0.4 cm in aggregate. Submitted in toto in 1 cassette.

Microscopic

There are two slides examined showing nineteen serial level sections demonstrating multiple fragments of colonic mucosa and one fragment of an invasive moderately differentiated adenocarcinoma consisting of neoplastic glandular

Microscopic(continued)

complexes with cribriform pattern lined by one to several strips of neoplastic columnar cells with enlarge vesicular nucleus, many with prominent nucleoli. Occasional mitotic figures are noted. Focal desmoplastic reaction is also observed.

CFG/kh