



C. H. Park, M.D., Lab Director
 C.F. Galang, M.D., Co-Director
 Y. S. Park, M.D., Pathologist
 H. Xu, M.D., Ph.D., Pathologist
 K. L. Cooper, M.D., Pathologist
 G. Sharma, M.D., Pathologist

812 Huron Road Suite 520, Cleveland, Ohio 44115 Office: 216-861-5846 Fax: 216-861-1720 Toll Free: 800-527-6446 www.OncoDiagnostic.com

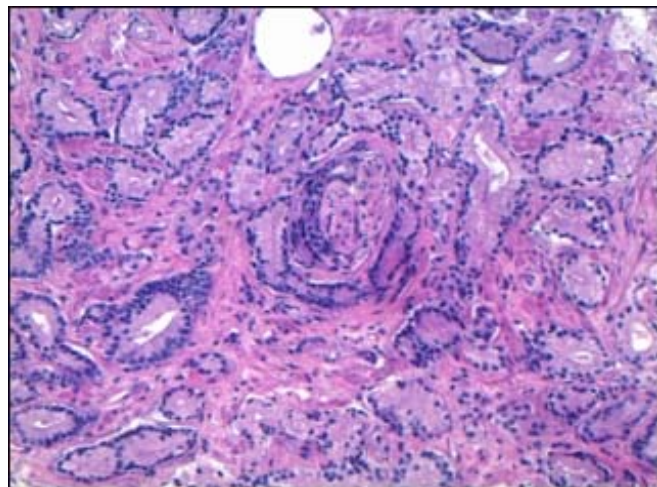
Account Name & Address
 ODL*ODL
 DR. JOSEPH SMITH
 812 HURON ROAD, SUITE 520
 CLEVELAND, OH 44115-1126
Phone: 216-861-5846 **Fax:** 555-5555
Cc: DR. AMEAD ATASSI

Patient Name: DOE, JOHN
Case Number: S2009-010658
Date of Birth: 07 18 1954
Age: 55
Collection Date: 07 07 2010
Received Date: 07 09 2010

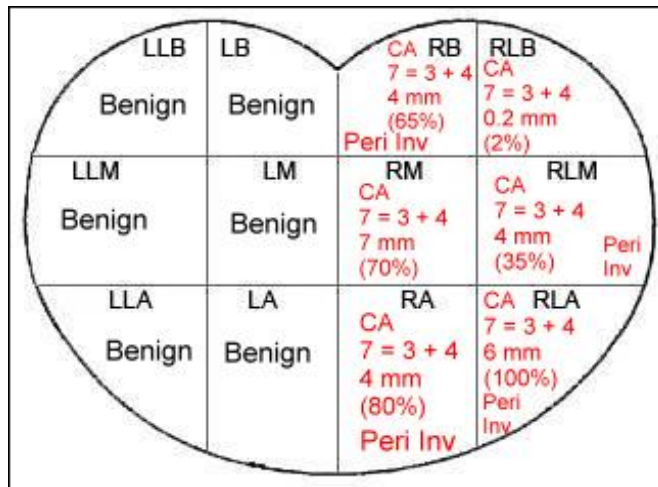
CLINICAL INFORMATION

PSA ng/ml: 4.08

IMAGE



RLA - Adenocarcinoma, 7=3+4



Diagnosis Summary

PROSTATE DIAGNOSIS

Site	Diagnosis
LA:	BENIGN PROSTATIC TISSUE WITH FOCAL MILD CHRONIC INFLAMMATION.
LLA:	BENIGN PROSTATIC TISSUE WITH FOCAL MILD CHRONIC INFLAMMATION.
LM:	BENIGN PROSTATIC TISSUE WITH FOCAL MILD CHRONIC INFLAMMATION.
LLM:	BENIGN PROSTATIC TISSUE WITH FOCAL MILD CHRONIC INFLAMMATION.
LB:	BENIGN PROSTATIC TISSUE WITH FOCAL MILD CHRONIC INFLAMMATION.
LLB:	BENIGN PROSTATIC TISSUE WITH FOCAL MILD CHRONIC INFLAMMATION.
Lt. Cytospins: YSP/GS/kr	BENIGN EPITHELIAL COMPLEXES.

Site	Diagnosis
RA:	ADENOCARCINOMA, GLEASON'S SCORE 7=3+4, 4 MM IN TUMOR LENGTH/5 MM CORE LENGTH (APPROXIMATELY 80% OF BIOPSIED TISSUE); PERINEURAL INVASION.
RLA:	ADENOCARCINOMA, GLEASON'S SCORE 7=3+4, 6 MM IN TUMOR LENGTH/6 MM CORE LENGTH (APPROXIMATELY 100% OF BIOPSIED TISSUE); PERINEURAL INVASION.
RM:	ADENOCARCINOMA, GLEASON'S SCORE 7=3+4, 7 MM IN TUMOR LENGTH/10 MM CORE LENGTH (APPROXIMATELY 70% OF BIOPSIED TISSUE).
RLM:	ADENOCARCINOMA, GLEASON'S SCORE 7=3+4, 4 MM IN TUMOR LENGTH/11 MM CORE LENGTH (APPROXIMATELY 35% OF BIOPSIED TISSUE); PERINEURAL INVASION.
RB:	ADENOCARCINOMA, GLEASON'S SCORE 7=3+4, 4 MM IN TUMOR LENGTH/6 MM CORE LENGTH (APPROXIMATELY 65% OF BIOPSIED TISSUE); PERINEURAL INVASION.
RLB:	MICROFOCAL ADENOCARCINOMA, GLEASON'S SCORE 7=3+4, 0.2 MM IN TUMOR LENGTH/9 MM CORE LENGTH (APPROXIMATELY 2% OF BIOPSIED TISSUE); PERINEURAL INVASION.
Rt. Cytospins:	GROUPS OF ADENOCARCINOMA CELLS.

GROSS DESCRIPTION

Bx Site	#Core/MM	# Slides Prepared	Bx Site	# Core/MM	# Slides Prepared
LA:	1 core	2 Histo; 1 Cyto	RA:	1 core and fragment	2 Histo; 1 Cyto
LLA:	1 core	2 Histo; 1 Cyto	RLA:	1 core and fragment	2 Histo; 1 Cyto
LM:	1 core	2 Histo; 1 Cyto	RM	1 core and fragment	2 Histo; 1 Cyto
LLM:	1 core	2 Histo; 1 Cyto	RLM:	1 core	2 Histo; 1 Cyto
LB:	1 core	2 Histo; 1 Cyto	RB:	1 core	2 Histo; 1 Cyto
LLB:	1 core	2 Histo; 1 Cyto	RLB	1 core and fragment	2 Histo; 1 Cyto

YOUNG S. PARK, M.D.
(Case signed 07 12 2010)